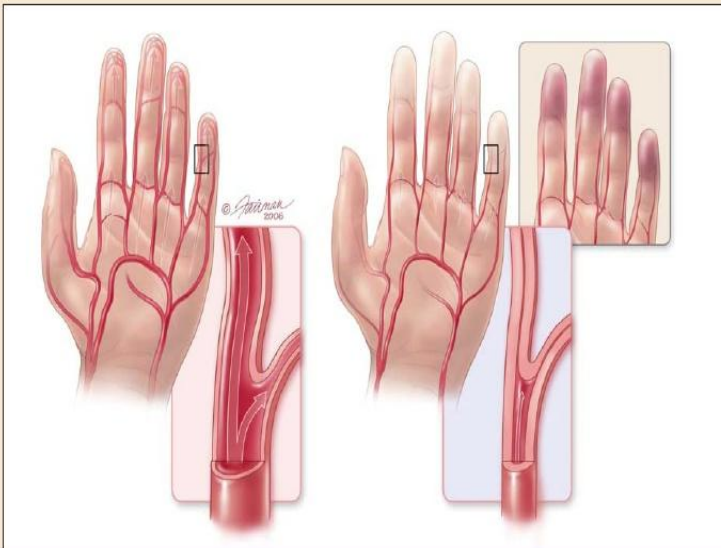


# Raynaud's Syndrome

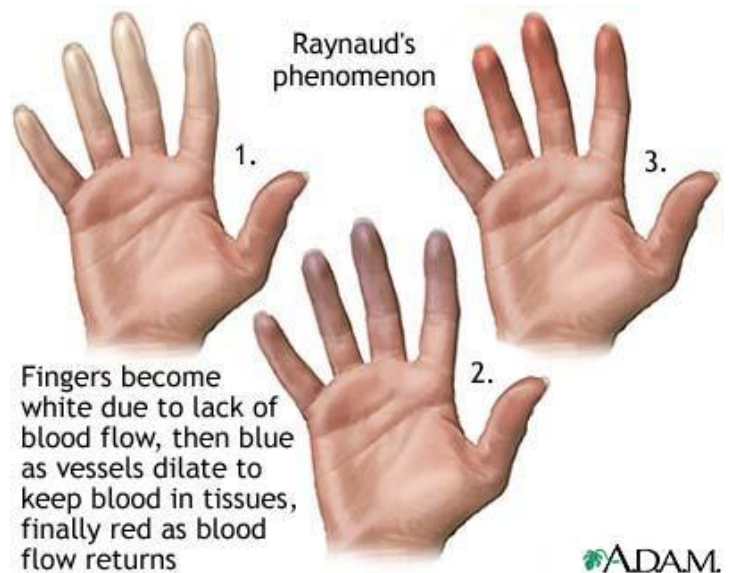
## Raynaud's Syndrome

FIGURE 1

Vascular changes that occur during acute Raynaud's disease



Digital arteries allow normal blood flow to the fingertips (left), but during an acute attack of Raynaud's disease, the arteries constrict and prevent blood flow to the fingertips (right). The insufficient blood flow results in hyperemia followed by pallor and cyanosis (upper insert, far right). Other areas that can be affected in an acute attack are the toes, nose, ears, lips, and nipples.



ADAM.

